

# Battery swallowing: original image

## Battery

Kayıpmaz Afşin Emre<sup>1</sup>, Taneri Birand<sup>1</sup>, Kavalci Cemil<sup>1</sup>

<sup>1</sup> Department of Emergency, Faculty of Medicine, Başkent University, Ankara, Türkiye.

A 5-year-old male patient presented to our emergency department with a complaint of accidentally swallowing a battery one hour prior. His medical history was unremarkable, with no chronic illnesses or medication use. Vital signs were within normal limits: heart rate 100 bpm, blood pressure 100/75 mmHg, and respiratory rate 16 breaths per minute. On physical examination, no abnormalities were detected. An abdominal X-ray revealed the presence of the battery in the gastrointestinal tract (Figure 1). The patient was admitted for outpatient follow-up. The next day, a repeat abdominal X-ray showed that the battery had progressed further along the gastrointestinal tract (Figure 2).

Foreign body ingestion occurs primarily in children and in specific high-risk adult populations.<sup>1,2</sup> Various objects, including coins, batteries, needles, bottles, and glass, are frequently encountered in the gastrointestinal system.<sup>2-4</sup> While sharp objects and batteries generally require surgical removal, blunt objects such as coins are often allowed to pass naturally through defecation.<sup>5</sup> In this case, the battery was managed conservatively, with the expectation of natural passage.

## Declarations

### Animal and Human Rights Statement

The authors declare that they are responsible for the scientific content of the article, including the study design, data collection, analysis and interpretation, manuscript preparation, and approval of the final version of the manuscript.

### Informed Consent

Written informed consent was obtained from the patient for publication of this case report and accompanying images.

## DOI:10.4328/ECAM42

Received : 26.11.2014

Accepted : 07.12.2014

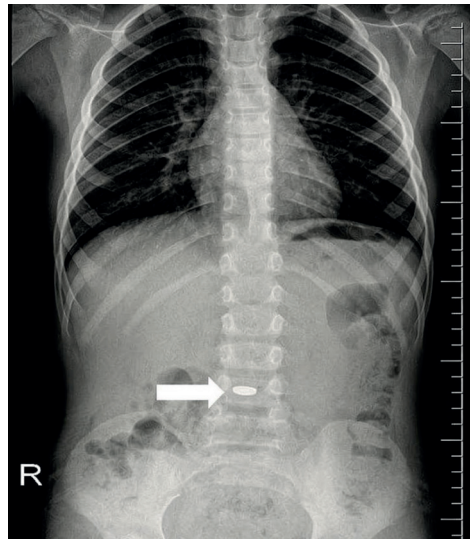
Published Online : 01.01.2015

Printed Online : 01.01.2015

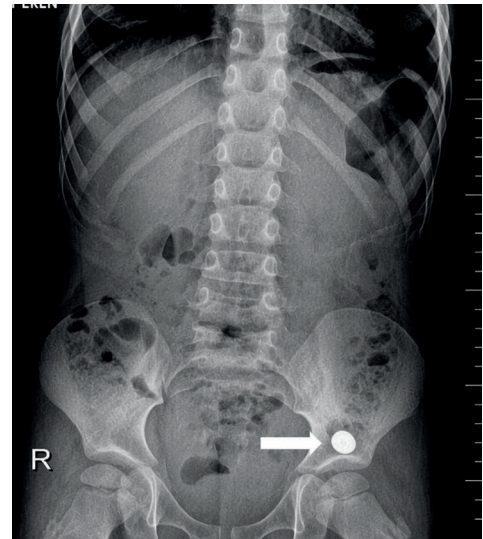
**Eu Clin Anal Med 2015;3(1). doi:10.4328/ECAM42**

**Corresponding Author:** Kayıpmaz Afşin Emre, Baskent University Faculty of Medicine, Emergency Department, Ankara, Türkiye.

**E-Mail:** aekayipmaz@yahoo.com



**Figure 1.** Battery was seen in abdomen X-ray at first day



**Figure 2.** Battery was seen in abdomen X-ray at next day

### Conflict of Interest

The authors declare that there is no conflict of interest.

### Funding

None.

### Scientific Responsibility Statement

The authors declare that they are responsible for the article's scientific content, including study design, data collection, analysis and interpretation, writing, and some of the main line, or all of the preparation and scientific review of the contents, and approval of the final version of the article.

### References

1. Ozsarac M, Demircan A, Sener S. Glass foreign body in soft tissue: possibility of high morbidity due to delayed migration. *J Emerg Med.* 2011;41(6):e125-e128. doi:10.1016/j.jemermed.2008.04.051
2. Zippi M, Febbraro I, De Felici I, et al. Foreign bodies in the upper gastrointestinal tract (personal experience). *Clin Ter.* 2007;158(4):291-295.
3. Sayhan MB, Gokdemir MT, Kavalci C. An unusual foreign body: a pendant. *J Pak Med Assoc.* 2010;60(7):600.
4. Çobanoğlu U, Aşker S, Sayır F. Esophageal foreign bodies. *JCAM.*
5. Telford JJ. Management of ingested foreign bodies. *Can J Gastroenterol.* 2005;19(10):599-601. doi:10.1155/2005/516195